

## A study of morphometric evaluation of jugular foramen in adult dry skulls of West Bengal based population

Anwesa Pal<sup>1</sup>, Soumali Biswas<sup>1\*</sup> and Arijit Majumdar<sup>2</sup>

<sup>1</sup>Department of Anatomy, Institute of Post Graduate Medical Education & Research, SSKM Hospital, 244 AJC Bose Road, Kolkata-700020, West Bengal, India and <sup>2</sup>Department of Pathology, Deben Mahato Government Medical College, Hatuara, Purulia-723147, West Bengal, India

**Received:** 20<sup>th</sup> February 2022; **Accepted:** 28<sup>th</sup> September 2022; **Published:** 01<sup>st</sup> October 2022

**Abstract:** *Aims and Objectives:* The jugular foramen is known to have a wide variation among different ethnicities for its anatomical variations and is also a well known area for pathological lesions such as glomus tumours, Schwannomas etc. The treatment of such lesions often involves drilling the bony area around the jugular foramen. The present study is the morphometric evaluation of the dimensions of jugular foramen in regard to the variability in shape and size of jugular foramen and the relationship between antero-posterior diameter (APD) and mediolateral diameter (ML) of jugular foramen on each side (right & left). *Methodology:* 100 dry adult human skulls were studied from Dept. of Anatomy, IPGMER, Kolkata, irrespective of their age. The morphological characteristics of all the skulls were examined with the help of Vernier calipers; taking into consideration their side. It was then followed by statistical analysis. *Results:* All the parameters of right jugular foramen were greater than the left side, except the distance of stylomastoid foramen from lateral margin of jugular foramen which was greater on the left side. Gender differences between various measurements of jugular foramen, presence of dome of jugular fossa, and compartmentalization patterns were reported. *Conclusion:* Thorough knowledge of morphometric findings of jugular foramen will be helpful for neurovascular surgeries with maximum safety and minimum mortality and morbidity.

**Keywords:** Jugular Foramen, Anteroposterior Diameter, Mediolateral Diameter, Human Dry Skull.

### Introduction

The jugular foramen is a bony hiatus consisting of a complicated bony architecture which transmits multiple significant neurovascular structures out of the base of the skull to the carotid space: Inferior petrosal sinus (anterior); gloss pharyngeal, vagus and accessory cranial nerves (middle); internal jugular vein (posterior) [1]. The jugular foramen is difficult to understand because of its anatomical complexity as well as population-specific, gender-specific and even laterality specific variations. The difficulties in exposing this foramen surgically are created by its deep location and proximity to vital structures, such as the carotid artery (anteriorly), the facial nerve (laterally), the hypoglossal nerve (medially) and the vertebral artery (inferiorly).

Most of the intracranial and extra cranial lesions of posterior cranial fossa may affect the structures in jugular foramen in addition to intrinsic

abnormalities. Pathologies like meningiomas, paraganglionomas, schwannomas and other inflammatory lesions of inner ear are known to affect the structures in jugular foramen. Most of the approaches for resection for these tumors such as retrosigmoid, transjugular craniotomy require partial petrosectomy traversing the jugular fossa. Thus, the knowledge of anatomical details and dimensions of jugular foramen would be a great help to these surgeons while approaching this area [2].

The Knowledge of variations and morphometric evaluation of jugular foramen is not only useful for neurosurgeons but also for anthropologists for ethnic and racial differences of the skulls of particular population [3].

Multiple studies including osteological, radiological and microdissections were

performed to find the compartmentalization and variations in the anatomy of jugular foramen, which led to various conflicting observations [4]. Moreover, there is paucity of data from the eastern Indian population and lacking altogether among Bengalees. The present study is undertaken for morphometric evaluation of jugular foramen in dry skulls of West Bengal based population.

**Material and Methods**

After receiving Institutional and ethical committee’s permission we carried out this institution based cross sectional observational study in the department of Anatomy, IPGME&R, Kolkata for 8 months duration from December 2020 to July 2021. We included 100 dry human skulls of unknown age and sex from different medical colleges of West Bengal, with due permission from the heads of the respective departments of Anatomy. We presume that the bones were collected from donated cadaver from population of West Bengal and adjacent states. Thus, we included 50 bones of right side and 50 left side skulls by convenient method of non-randomised sampling.

All the skulls were normal and were devoid of any malformations and erosions. Simple vernier calipers were used to take all the measurements. The measurements were recorded on both sides for each skull. The antero-posterior, medio-lateral and the interjugular distance of all the skulls were noted. The skulls were also examined for the presence of any dome or septation. The distance between stylomastoid foramen to the lateral aspect of jugular foramen on both sides was also noted. All the measurements were taken 3 times each by 2 observers and the mean value of all such readings were taken into consideration, in order to avoid observer bias as much as possible.

**Results**

The results of the quantitative parameters of jugular foramen are shown in Tables. All the parameters of the endocranial aspect of right jugular foramen were greater than the left side but were not significant (table-1) and the type of septation is shown in Table 2.

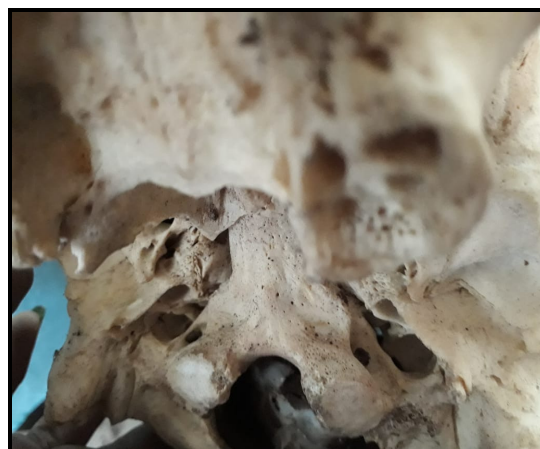**Table-1: Comparison of dimensions (mean ± standard deviation) of jugular foramen on both sides (n=100)**

	Right side	Left side	P value
Antero-posterior diameter	8.75 ±1.4	7.90 ±1.8	0.5
Medio-lateral diameter	13.13 ±1.3	11.89 ±1.8	0.3
SMF to Lateral jugular foramen distance	4.36 ±1.6	5.10 ±1.4	0.4

**Table-2: Comparison of septum of jugular foramina (n=100)**

Septum	Right side	Left side	Bilateral	Total
Complete	5	9	7	21
Partial	20	15	9	44
No septum				35

**Fig-1:** Shows incomplete septa in Right side and a complete septa in left side of jugular foramen

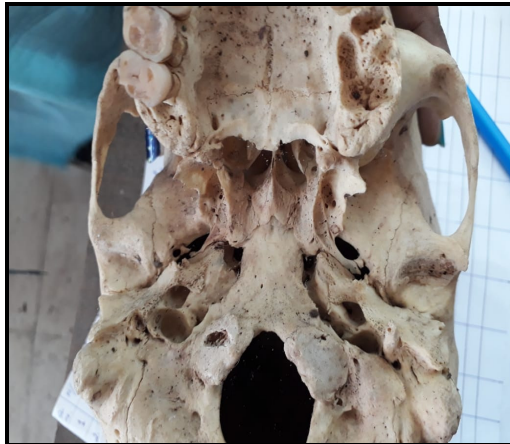


The dome of jugular foramen was present bilaterally in 12% skull, while 22% skull on right side and 26% skull in left side. It was absent in 40% skull.

**Table-3: Status of dome in the jugular foramen**

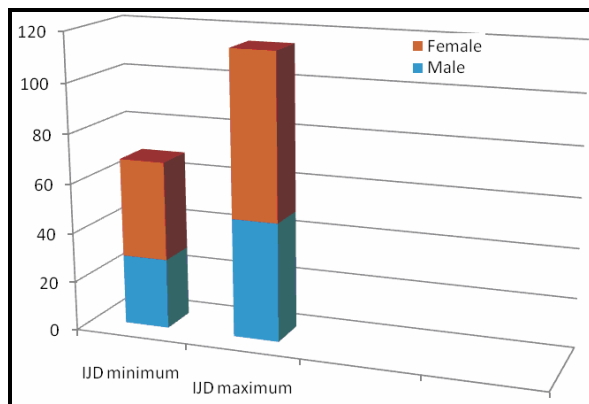
Dome	Right	Left	Bilateral	Total
Present	22	26	12	60
Absent				40

**Fig-2:** Shows Bilateral presence of domed jugular foramen

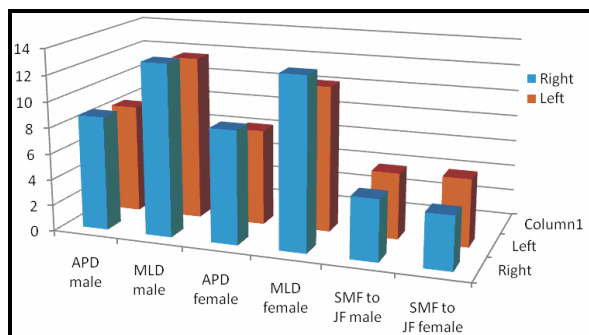


Gender differences between various measurements of jugular foramen were demonstrated in Figure 3 and Figure 4.

**Fig-3:** Interjugular distance (IJD) [mm] in males and females



**Fig 4:** Comparison of dimensions (mean± standard deviation in mm) of jugular foramen in both genders [IJD- Interjugular foramen distance, APD- Antero-posterior diameter, MLD- medio-lateral diameter, SMF- Stylomastoid foramen, JF- jugular foramen]



**Discussion**

Jugular foramen is located between the petrous part of the temporal bone and occipital bones. It connects the posterior cranial fossa and the jugular fossa. However, the jugular foramen is difficult to understand in three dimensional form and even difficult to assess surgically due to its deep location and the presence of surrounding neurovascular structures. The variant anatomy of the jugular foramen and variation of its size attract attention of neurosurgeons. Also the relationship of the structures which pass through the foramen is of medical and surgical interest [5].

The foramina show variation in presence of dome, septation, and dimensions in different population. These variations are of clinical importance [6]. Standard anatomical textbook states that the superior sagittal sinus drains into the right transverse sinus, thus the right jugular foramen is expected to be larger than the left. [7]. But there are variations in the anatomy of intracranial venous sinuses which lead to variations of the internal jugular veins and subsequent the size and shape of the jugular foramen [8].

In the present study, the mean anteroposterior diameter (APD) of the jugular foramen on right and left were  $8.75 \pm 1.4 \text{ mm}$  and  $7.90 \pm 1.8 \text{ mm}$ , and mediolateral (MLD)  $13.13 \pm 1.3 \text{ mm}$  and  $11.89 \pm 1.8 \text{ mm}$  on the right and left sides respectively (Table no.1). Our findings were very nearer to previous works. Pereira et al found mean anteroposterior diameter to be 9.21mm and 8.65mm and mediolateral diameter to be 15.82mm and 15.86mm on right and left side respectively in Southern Brazilian population [6].

In a study of Nigerian skull, Idowu et al reported the mean width as 10.2mm, 9.52mm and the length as 14.11mm, 13.9mm on right and left side respectively [9]. Anjali Singla et al showed in their study that anteroposterior diameter and mediolateral diameter was found to be 9.32mm, 7.34mm and 15.65mm, 14.85mm on right and left side respectively in North West region [10]. Vijisha et al found the width and length of jugular foramen as 12.13mm, 9.27mm and 17.3mm, 15.3mm

respectively in right and left side in skulls from Tamil Nadu [11]. In all these above studies right jugular foramen was found to be larger than the left. But diameters in these skulls vary from each other. According to Wysocki et al results variations can be due to racial and individual factors [12]. In turn, Adams et al. noticed that there was an association between jugular foramen dominance and hand preference (a larger right jugular foramen occurs more often in right-handed patients) [13]. No statistically significant gender differences were obtained in our study.

In this study incidence of septation is 65%. There are Bilateral complete in 7%, unilateral in 14% (5% RT, and 9% LT). Partial in 44%. Vljaković et al. showed in their results, complete bony bridges of the jugular foramen in 24% of examined skulls [14]. Patel and Singel who studied the Indian Saurashtra region, observed complete septation on the right side in 23.1%, on left side in 17.6%; partial septation on the right side in 49.5%, and on left side in 59.3% skulls [15].

In a study of 300 Anatolian skulls, Hatiboglu et al observed complete septation in 5.6% and 4.3% skull and partial septation in 2.6% and 19.6% skull on right and left side respectively [16]. Patel and Singel reported complete septum on right side 23.1% and left side 17.6%; partial septum on septum on right side 49.5% and left side 59.3% in a study of Shaurashtra region [15]. The cause of variations of septation frequency may be of racial factor, genetic or developmental. The partial septation of foramina may be completed in the living by a fibrous septum [17]. Septation must be kept in mind during surgical approach to lesions within the foramen [18].

Another important anatomical feature of the jugular foramina is presence of dome. In this study the bilateral dome is present in 12% and unilateral dome in 48% of skull examined. These results are not comparable to this by Singla et al. who reported bilateral dome in 66% of cases [10]. Pereira et al found bilateral dome in 68.5% [6]. The presence of dome indicates the presence of well-expressed superior bulb of internal jugular vein [19]. The absence of domed bony roof indicates that the superior jugular bulb is poorly developed or absent in such cases and may not form the floor of middle ear cavity. Thus, there is

less risk of penetration of these tumors into the middle ear in these cases [20]. The observed variation of JF is possibly due to constitutional, racial or genetic factors.

As the facial nerve emerges from the stylomastoid foramen, the distance of stylomastoid foramen (SMF) to the lateral margin of jugular foramen can serve as a guide for neurosurgeons, during the procedure of rerouting of facial nerve. Our study shows that the distance of stylomastoid foramen are  $4.36 \pm 1.6$  mm and  $5.10 \pm 1.4$  mm from the lateral margins of right and left jugular foramen, respectively.

This side difference in the distance of facial nerve from jugular foramen was statistically nonsignificant ( $p$  value = 0.4). These dimensions are comparable to the earlier study by Kotgirwar and Athavale [21] Sushant Swarup Jha et al. shows that the facial nerve lies at a mean distance of 4.76 mm and 5.13 mm from the lateral margins of right and left jugular foramen, respectively. Overall, males showed greater length of SMJF than females but were also not statistically significant [20].

### Conclusion

The variations in the size, shapes and compartments of jugular foramen might be a part of the ongoing evolutionary process. This study expected to give a clear understanding of the jugular foramen anatomy and recorded reported morphometric variations of the same, besides adding data on the East Indian population, particularly Bengalees. Knowledge of it is very helpful for surgeons dealing with a space occupying lesion in jugular foramen.

Good preoperative imaging of the foramen is recommended to avoid injury of its contents due to foramen variability. The foramina are larger on the right than the left in Indian population. Existence of genetic factors in the expression of the bridging trait is known, the bridging trait can thus be studied in anthropological studies in different study populations. So, the knowledge of these variations may be important for neurosurgeons, radiologists as well as anthropologists.

**Financial Support and sponsorship:** Nil

**Conflicts of interest:** There are no conflicts of interest.

### References

1. Standring Susan, Berkovitz Barry KB. Head and Neck. In: Gray's Anatomy the Anatomical basis of clinical practice. 40th edition. Elsevier Churchill Livingstone, 2008; 409-417.
2. Matsushima K, Kohno M, Komune N, Miki K, Matsushima T, Rhoton AL, Jr Suprajugular extension of the retrosigmoid approach: Microsurgical anatomy: Laboratory investigation. *J Neurosurg*, 2014; 121:397-407.
3. Vidya CS. A Study of mormphometric evaluation of jugular foramen in adult dry skulls of Mysuru based population. *Int J Intg Med Sci*, 2017; 4(6):498-500.
4. Hasan DV, Hasan R, Nanayakkara BG, Dilrukshi A, Fernando E. A comparative study of the anatomy of the jugular foramen and its variations in dried adult human skulls in Sri Lankan Population. *International Journal of Scientific Engineering and Science*, 2019; 3(3):25-28.
5. Kumar A, Akhtar J, Kumar A. Variations in jugular foramen of human skull. *Asian Journal of Medical Sciences*, 2015; 6(2):95-98.
6. Pereira GAM, Lopes PTC, Santos AMPV, Krebs WD. Morphometric aspects of the jugular foramen in dry skulls of adult individuals in Southern Brazil. *J Morpfol Sci*. 2010; 27(1):3-5.
7. Standring S. Gray's Anatomy. The Anatomical Basis of Clinical Practice. 40th ed. *Edinburg: Churchill & Livingstone*, 2008; 423-434.
8. Saheb S, Mavishetter G F, Thomas ST, Prasanna LC, Muralidhar P. A morphometric study of the jugular foramen in human adult skulls of south India. *J Biomed Sci Res*. 2010; 2:240-243.
9. Idowu OE. The jugular foramen - A morphometric study. *Folia Morphol*, 2004; 63:419-422.
10. Singla A, Sahni D, Aggarwal A et al. Morphometric study of the Jugular foramen in Northwest Indian Population. *J of Postgraduate Medicine, Education and Research*, 2012; 46(4):165-171.
11. Vijisha P, Bilodi AK, Lokeshmaran. Morphometric Study of Jugular foramen in Tamil nadu region. *National J of Clinical Anatomy*, 2013; 2 (2):71-74.
12. Wysocki J, Reymond J, Skarzynski H and Wrobe B. The size of selected human skull foramina in relation to skull capacity. *Folia Morphologica*, 2006; 66: 301-308.
13. Adams WM, Jones RL, Chavda SV, Pahor AL. CT assessment of jugular foramen dominance and its association with hand preference. *Journal of Laryngology & Otology*, 1997; 111:290-292.
14. Vljaković S, Vasović L, Daković-Bjelaković M, Stanković S, Popović J, Čukuranović R. Human bony jugular foramen: Some additional morphological and morphometric features. *Med Sci Monit*. 2010; 16(5):140-146.
15. Patel MM, Singel TC. Variations in the structure of the jugular foramen of the human skull in Saurashtra region. *J Anat Soc India*, 2007; 56(2):34-37.
16. Hatiboglu MT, Anil A. Structural variations in the jugular foramen of the human skull. *J Anat*. 1992; 180:191-196.
17. Tubbs RCG. Dural septation on the inner surface of the jugular foramen: An anatomical study. *J. Neurol. Surg*. 2015; 76:214-217.
18. Khanday S, Ramesh Kumar, Melani R, Ashfaq U, Sajad H. Morphological and morphometric study of jugular foramen in South Indian population. *Int. J. Anat. Res*. 2013; 1:122-127.
19. Sasindran V, Abraham S, Hiremath S, Joseph A. High-riding jugular bulb: A rare entity. *Indian J. Otolaryngol*. 2014; 20:129.
20. Das SS, Saluja S, Vasudeva N. Complete morphometric analysis of jugular foramen and its clinical implications. *J Craniovertebr Junction Spine*. 2016; 7(4):257-264.
21. Kotgirwar S, Athavale S. Morphometric study of jugular foramen in adult South Indian skulls. *J Anat Soc India*. 2013; 62:166-169.

**Cite this article as:** Pal A, Biswas S and Majumdar A. A study of morphometric evaluation of jugular foramen in adult dry skulls of West Bengal based population. *Al Ameen J Med Sci* 2022; 15(4): 295-299.

This is an open access article distributed under the terms of the Creative Commons Attribution-Non Commercial (CC BY-NC 4.0) License, which allows others to remix, adapt and build upon this work non-commercially, as long as the author is credited and the new creations are licensed under the identical terms.

\*All correspondences to: Dr. Soumali Biswas, Assistant Professor, Department of Anatomy, Institute of Post Graduate Medical Education & Research, SSKM Hospital, 244 AJC Bose Road, Kolkata-700020, West Bengal, India. E-mail: drsoumali.biswas26@gmail.com